




Contents lists available at ScienceDirect

Injury

journal homepage: [www.elsevier.com/locate/injury](http://www.elsevier.com/locate/injury)



## The effect of haematoma aspiration on intra-articular pressure and pain relief following Mason I radial head fractures

Konstantinos T. Ditsios\*, Stavros I. Stavridis, Anastasios G. Christodoulou

1st Orthopaedic Department of Aristotle University, 'G. Papanikolaou' General Hospital, Exohi, 57010 Thessaloniki, Greece

### ARTICLE INFO

#### Article history:

Accepted 6 September 2010

#### Keywords:

Radial head fracture  
Elbow aspiration  
Haematoma aspiration  
Intra-articular pressure  
Pain relief

### ABSTRACT

**Background:** The aspiration of the accompanying haematoma by Mason type I radial head fractures is advocated by several authors to achieve an analgesic effect. The purpose of this study was to investigate the effect of haematoma aspiration on intra-articular pressure and on pain relief after Mason I radial head fractures.

**Materials and methods:** A total of 16 patients (10 men and six women, age 23–47 years) with an isolated Mason I radial head fracture were subjected to haematoma paracentesis. Initially, intra-articular pressure was measured by using the Stryker Intra-Compartmental Pressure Monitor System. After haematoma aspiration, a new pressure measurement without moving the needle was performed. Pain before and after haematoma aspiration was evaluated by using an analogue 10-point pain scale.

**Results:** Intra-articular elbow pressure prior to haematoma aspiration varied from 49 to 120 mmHg (median, 76.5 mmHg), while following aspiration, it ranged from 9 to 25 mmHg (median, 17 mmHg). The median quantity of the aspirated blood was 2.75 ml (range, 0.5–8.5 ml). Patients reported a decrease in the visual analogue score (VAS) for pain from 5.5 (4–8) before to 2.5 (1–4) after aspiration. Decrease for both pressure and pain was statistically significant ( $p = 0.005$ ).

**Conclusion:** The formation of an intra-articular haematoma in the elbow joint following an undisplaced Mason I radial head fracture leads to a pronounced increase of the intra-articular pressure accompanied by intense pain for the patient. The aspiration of the haematoma results in an acute pressure decrease and an immediate patient relief.

© 2010 Elsevier Ltd. All rights reserved.

### Introduction

Radial head fractures are very common and account for 26% of all fractures of the elbow and approximately 1.5–4% of all fractures in adults.<sup>7,8</sup> As much as 85% of these fractures occur between the third and sixth decade of age. Radial head fractures usually result from a fall on an outstretched arm with the elbow in pronation and partial flexion or, in rare cases, direct trauma.<sup>1,12</sup>

Radial head fractures can be classified according to the Mason–Johnston classification.<sup>10</sup> Mason type I fractures are the non-displaced radial head fractures and are treated conservatively with early mobilisation and excellent results,<sup>6,11</sup> while in other types, surgical intervention is usually indicated.<sup>16</sup>

The aspiration of the haematoma that accompanies Mason type I radial head fractures is advocated by several authors to achieve an

analgesic effect,<sup>4,9</sup> but available evidence is still obscure to recommend it as a routine procedure.<sup>2</sup>

The purpose of this study was to investigate the effect of haematoma aspiration on intra-articular pressure and on pain relief after Mason I radial head fractures.

### Materials and methods

Our study was performed from June 2008 to December 2009 and was approved by the hospital's ethical committee for clinical studies and was in accordance with the Greek guidelines for clinical studies. All patients had the treatment procedure explained in detail and all signed a consent form to enrol in the study. Afterwards, a short questionnaire with the patient's demographic data was filled.

Criteria for patients to be included in the study were defined as follows:

- (1) an isolated, low-energy elbow trauma, without concomitant injuries or fractures;
- (2) referral to the emergency department within 6 h after injury;

\* Corresponding author at: Redestou, Kardia, 57500 Mikra, Greece.

Tel.: +30 2392064784; fax: +30 2392064784.

E-mail address: [ditsiosk@otenet.gr](mailto:ditsiosk@otenet.gr) (K.T. Ditsios).

- (3) radiologic confirmation (elbow antero-posterior and lateral views) of an undisplaced, Mason type I radial head fracture;
- (4) existence of symptoms and signs consistent with such an injury;
- (5) lack of any tenderness on the medial site of the elbow at clinical examination to exclude a medial collateral ligament injury; and
- (6) willingness to participate in the study.

Accordingly, exclusion criteria were defined as follows:

- (1) existence of concomitant injuries or fractures;
- (2) treatment more than 6 h after injury;
- (3) suspected medial collateral ligament injury; and
- (4) refusal to participate in the study.

Aspiration was performed in all cases in the emergency department by the same surgeon. In his absence, no patients were recruited into the study.

The pressure measurement and haematoma aspiration procedures were performed as follows.

With the patient lying in supine position, the forearm was placed on the patient's abdomen with the injured elbow flexed at about 80° to maximise the patient's comfort. Under aseptic conditions, an 18-g needle with the device for intra-compartmental pressure measurement (Intra-Compartmental Pressure Monitor System, Stryker®<sup>®</sup>, MI, USA) was inserted after palpation of the haematoma. The exact insertion point was in the centre of a triangle formed by the radial head, the lateral epicondyle and the olecranon tip, as described by Quigley.<sup>15</sup> The correct position of the needle was verified with the pressure indications during insertion. If the needle was in the surrounding tissues, pressure indications were less than 10 mmHg. The insertion of the needle into the haematoma was accompanied by increased pressure indications. No regional anaesthesia was performed, to avoid interference with pressure measurement and pain evaluation following haematoma aspiration.

After penetrating the haematoma, the needle was held stably and the pressure indication was registered after 30 s. Afterwards, with the needle held in place, the device was removed and a 10-ml syringe was applied to aspirate the haematoma. During aspiration, the needle was held steadily in the same position and any movements were avoided. When the blood aspiration was completed, the syringe was removed, the contained blood quantity registered and the pressure measurement device was put back in place for post-aspiration pressure measurement. After 30 s, the indicated pressure was registered. This 30-s interval was used to standardise for the effects of capsular viscoelasticity and fluid flow across the synovium.<sup>14</sup>

Finally, the patients were asked to evaluate their pain before and after treatment by using a VAS pain.

After completing the evaluation procedure, the elbow was immobilised in a brachial–elbow–wrist back slab in 80° flexion. The back slab was applied only after pain evaluation by the patient was completed, to avoid any possible interference. The elbow was kept immobilised for 8–10 days, according to our standard protocol for conservative treatment of Mason type I radial head fractures. After 8–10 days, the patients were examined in our outpatient clinic and were asked to retrospectively evaluate their pain, especially the pain felt within 48 h after aspiration.

#### Statistical analysis

Changes in intra-articular pressure and VAS for pain were assessed with the non-parametric Wilcoxon signed ranks test due to the small sample size. All reported *p* values were two-tailed with *p* < 0.05 considered as significant and analyses were conducted

using Statistical Package for Social Sciences (SPSS) 15 (SPSS, Inc., Chicago, IL, USA).

#### Results

According to our inclusion criteria, 26 patients were eligible to be included in the study, but 10 of them refused the proposed haematoma aspiration.

The 16 patients that agreed to participate in our study (10 men, six women; age 23–47 years, median 33.5 years) referred to the emergency department of our hospital after suffering a low-energy elbow trauma.

In three cases, the mechanism of injury was a direct hit to the elbow, while 13 of the patients reported a fall on an outstretched hand. There were 11 right and five left elbows injured; the involved upper limb was the dominant one in 14 patients.

The mean follow-up time was 8.9 days (range, 8–10 days) as follow-up time ended at the outpatient control time point, where the back slab was removed.

The intra-articular elbow pressure prior to haematoma aspiration varied from 49 to 120 mmHg (median 76.50 mmHg), while following aspiration, it ranged from 9 to 25 mmHg (median 17 mmHg). This decrease in intra-articular pressure was statistically significant (*p* = 0.005) (Fig. 1).

The median quantity of the aspirated blood was 2.75 ml, ranging from 0.5 to 8.5 ml. According to the results of pain evaluation, the median pain score prior to treatment was 5.5 points (range, 4–8 points), while it decreased to a median of 2.5 points (range, 1–4 points) following haematoma aspiration. This decrease was also found to be statistically significant (*p* = 0.005) (Fig. 2).

The whole procedure was well tolerated by all patients and no early or late complications resulting from the aspiration procedure were reported.

When the patients were re-examined at the outpatient clinic, none of them reported a significant pain increase after aspiration, and all the patients claimed that the achieved pain relief was sustained.

#### Discussion

In our study, we aimed to investigate the effect of haematoma aspiration on intra-articular pressure and on pain relief after Mason I radial head fractures.

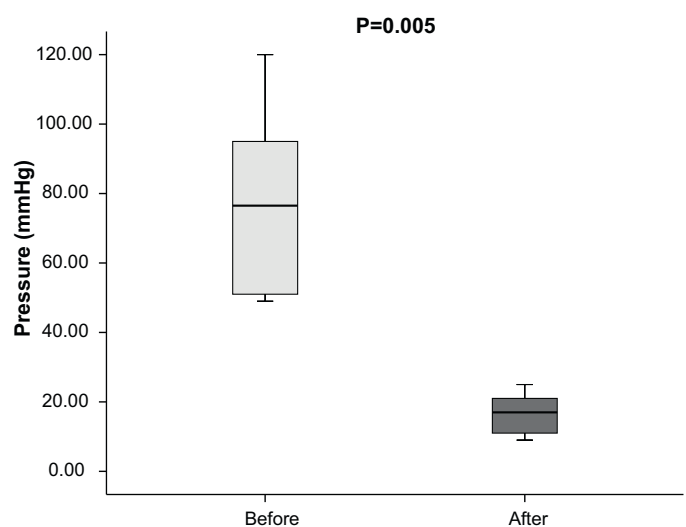
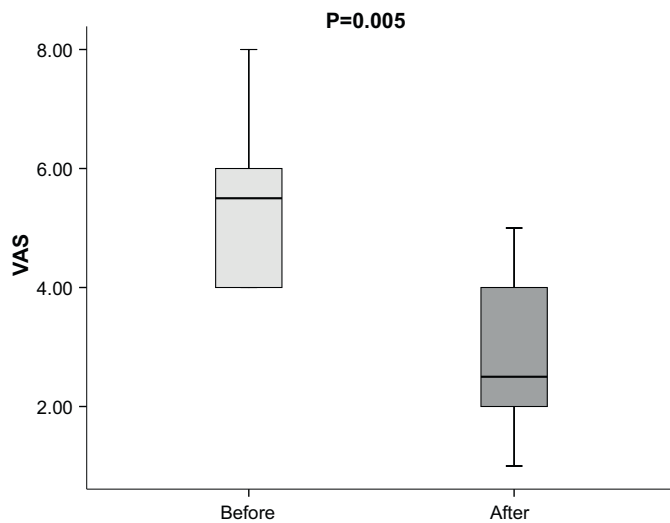


Fig. 1. Box-plot of elbow intraarticular pressure before and after aspiration (Wilcoxon signed ranks test *p* = 0.005). Elbow intraarticular pressure decreased significantly after aspiration (*p* = 0.005).



**Fig. 2.** Boxplot of VAS score for pain before and after aspiration (Wilcoxon signed ranks test  $p = 0.005$ ). VAS score for pain decreased significantly after aspiration ( $p = 0.005$ ).

Our results demonstrated a statistically significant decrease of median intra-articular elbow pressure (76.5 mmHg prior aspiration to 17 mmHg afterwards) as well as of pain perception (ranging from VAS 5.5 prior to aspiration to 2.5 afterwards) immediately after haematoma aspiration. The median quantity of aspirated blood was 2.75 ml.

Our findings support the analgesic effectiveness of haematoma aspiration following radial head fractures and are in accordance with various clinical studies, which prospectively demonstrated that elbow aspiration with<sup>9</sup> or without<sup>4</sup> local anaesthetic application resulted in significant patient relief as well as in an earlier return of motion.

Our measured preaspirational intra-articular pressure values (median 76.50 mmHg; range, 49–120 mmHg) are very similar to those reported by O'Driscoll in his cadaveric study (mean 80 mmHg, 95% confidence interval 54–108 mmHg) as able to cause capsular rupture.<sup>14</sup> These findings indicate that the formation of haematoma following a Mason type I radial head fracture causes a severe distension of the joint capsule almost reaching its maximum capacity and resulting in an intra-articular pressure increase extremely prone to capsular rupture.

In this cadaveric study, it was found that the capacity of the elbow joint capsule was ~20 ml and the lowest intra-articular pressure was measured at 80° of flexion. This position of maximum compliance might be interpreted as defining the 'resting position' of the elbow.<sup>14</sup> The typical clinical picture of the injured patient holding his elbow flexed at about 80° and avoiding any kind of movement reflects his effort to minimise pain and discomfort by achieving the position of maximum compliance and thus, minimum intra-articular pressure.

A similar cadaveric study showed that there is a linear relationship between intra-articular fluid volume and decreased range of motion in the elbow for a volume ranging from 0 to 25 ml with increased signs of capsular rupture after 20 ml of fluid were injected.<sup>13</sup>

Finally, in a study conducted with human subjects, the mean elbow joint capacity measured was 14 ml.<sup>5</sup> Because this study involved living patients, the capacity of the elbow was defined as the volume required to exceed an intra-articular pressure of 50 mmHg rather than the volume needed to cause rupture, as was the case in the above-mentioned cadaveric study. The pressure of 50 mmHg was below the lower 95% confidence interval for pressures that may cause capsular rupture.<sup>14</sup>

We found that the median quantity of aspirated blood was 2.75 ml, ranging from 0.5 to 8.5 ml. The range of these values could be interpreted as follows.

First, they are far beyond the maximum elbow capacity, indicating that the integrity of the joint capsule was preserved. Previous studies reported larger quantities of aspirated blood from 2 to 26 ml,<sup>4,9</sup> but since these studies also included Mason type II and type III radial head fractures, it is logical to assume that in such cases of more severe fractures, the joint capsule could be ruptured more easily in contrast to our study of Mason type I fractures.

Second, according to the bilinear pattern of the pressure/volume relationship for the intact elbow joint capsule<sup>14</sup> when reaching the upper limits of the curve, even a small fluid increase can cause a disproportionate increase in intra-articular pressure. Respectively, the aspiration of even a small amount of fluid can lead to a dramatic decrease of elbow joint intra-articular pressure and acute pain relief.

Our findings of post-aspiration elbow joint pressure ranging from 9 to 25 mmHg (median 17 mmHg) correlate well with similar findings of intra-articular pressure in normal elbows.<sup>5</sup>

Amongst the strengths of our study is the increased homogeneity of the group, achieved through the strict inclusion and exclusion criteria used, with only patients having suffered a radiologically confirmed, isolated Mason type I radial head fracture being included. This is particularly important as capsular rupture that usually occurs in Mason type II or higher fractures may cause an intra-articular pressure decrease and subsequent pain relief. We deliberately avoided the use of any local anaesthetic to avoid any interference of its action in evaluating the analgesic effect of haematoma aspiration as well as in pressure measurement before and after joint aspiration. According to a recent study, the intra-articular use of local anaesthetic after joint aspiration did not offer any benefit over aspiration alone.<sup>3</sup>

Our study also has several limitations. First, we did not use a control group to directly compare our findings. Because normal joint pressures have been extensively studied in the literature, we thought that this would be of no significant value. Furthermore, it proved extremely difficult to convince patients to enrol in this study to allow intra-articular pressure measurement of their uninjured elbow, what would have been undoubtedly the ideal control group. We further did not investigate the long-term results of elbow aspiration. Because we included only Mason type I fractures in our study, a group where the efficacy of conservative treatment is well established, we focussed solely in the immediate effects of elbow haematoma aspiration. Although it could be argued that the sustenance of pain relief could be partially attributed to elbow immobilisation following aspiration, it is reasonably to believe that the analgesic effect is mainly achieved with the haematoma aspiration. According to literature,<sup>24,9</sup> reformation of the haematoma within the first 48 h does not routinely occur, and if it does, it lacks any clinical significance. Our results further support this finding. Finally, it could be argued that the number of patients is relatively small, but it appears that the increased statistical significance of our results compensates for this.

As the most appropriate treatment for radial head fractures still remains a matter of controversy,<sup>16</sup> well-designed clinical trials with adequate statistical power are needed to establish conservative and surgical treatment guidelines for all types of these common fractures.

## Conclusions

In summary, our results demonstrate that haematoma formation following a Mason type I radial head fracture causes a dramatic increase of intra-articular pressure, almost reaching the

limits of joint capsule rupture. In such a case, the aspiration of even a small amount of liquid results in a significant pressure drop and subsequent pain relief. As elbow joint aspiration has proven to be a safe and reliable procedure without significant complications, we would advocate its use within the conservative treatment of Mason type I radial head fractures, for eliminating the risk of capsular rupture and achieving immediate pain relief.

#### Conflict of interest statement

There exists no conflict of interest regarding this work.

#### References

- [1] Amis AA, Miller JH. The mechanisms of elbow fractures: an investigation using impact tests in vitro. *Injury* 1995;26(3):163–8.
- [2] Carley S. The role of therapeutic needle aspiration in radial head fractures. *J Accid Emerg Med* 1999;16(4):282.
- [3] Chalidis BE, Papadopoulos PP, Sachinis NC, Dimitriou CG. Aspiration alone versus aspiration and bupivacaine injection in the treatment of undisplaced radial head fractures: a prospective randomized study. *J Shoulder Elbow Surg* 2009;18(5):676–9.
- [4] Dooley JF, Angus PD. The importance of elbow aspiration when treating radial head fractures. *Arch Emerg Med* 1991;8(2):117–21.
- [5] Gallay SH, Richards RR, O'Driscoll SW. Intraarticular capacity and compliance of stiff and normal elbows. *Arthroscopy* 1993;9(1):9–13.
- [6] Gebauer M, Rucker AH, Barvencik F, Rueger JM. Therapy for radial head fractures. *Unfallchirurg* 2005;108(8):657–67.
- [7] Herbertsson P, Josefsson PO, Hasserijs R, et al. Fractures of the radial head and neck treated with radial head excision. *J Bone Joint Surg Am* 2004;86-A(9):1925–30.
- [8] Herbertsson P, Josefsson PO, Hasserijs R, et al. Uncomplicated Mason type-II and III fractures of the radial head and neck in adults. A long-term follow-up study. *J Bone Joint Surg Am* 2004;86-A(3):569–74.
- [9] Holdsworth BJ, Clement DA, Rothwell PN. Fractures of the radial head—the benefit of aspiration: a prospective controlled trial. *Injury* 1987;18(1):44–7.
- [10] Johnston GW. A follow-up of one hundred cases of fracture of the head of the radius with a review of the literature. *Ulster Med J* 1962;3151–6.
- [11] Mason ML. Some observations on fractures of the head of the radius with a review of one hundred cases. *Br J Surg* 1954;42(172):123–32.
- [12] McGinley JC, Hopgood BC, Gaughan JP, et al. Forearm and elbow injury: the influence of rotational position. *J Bone Joint Surg Am* 2003;85-A(12):2403–9.
- [13] McGuigan FX, Bookout CB. Intra-articular fluid volume and restricted motion in the elbow. *J Shoulder Elbow Surg* 2003;12(5):462–5.
- [14] O'Driscoll SW, Morrey BF, An KN. Intraarticular pressure and capacity of the elbow. *Arthroscopy* 1990;6(2):100–3.
- [15] Quigley TB. Aspiration of the elbow joint in the treatment of fractures of the head of the radius. *N Engl J Med* 1949;240(23):915.
- [16] Struijs PA, Smit G, Steller EP. Radial head fractures: effectiveness of conservative treatment versus surgical intervention. A systematic review. *Arch Orthop Trauma Surg* 2007;127(2):125–30.